

LETTER TO THE EDITOR

EFFICACY OF SODIUM HYALURONATE AND SYNTHETIC AMINOACIDS IN POST-EXTRACTIVE SOCKET IN PATIENTS WITH LIVER FAILURE: SPLIT MOUTH STUDY

N. COCERO, T. RUGGIERO, A. PEZZANA, M. BEZZI and S. CAROSSA

*Oral Surgery Department, Department of Surgical Sciences, Dental School, University of Turin, Turin, Italy**Received June 12, 2019 – Accepted September 27, 2019*

To the Editor,

In recent years, among the new biomaterials used in dentistry the focus has been on products based on amino acids and hyaluronic acid (1). In this study we evaluated the effectiveness of hyaluronic acid gel, a new medical device that acts on fibroblasts to improve wound healing, composed of hyaluronic acid (HA) and aminoacids (AA) collagen precursors, L-lysine, L-proline, L-leucine and glycine. The system is composed by Glycol propylene e carbopol, HA e AA; the HA molecular weight is 1.500 KDalton, and it works at pH 5.5 – 6.5

In vivo and *in vitro* studies show that fibroblasts treated with HA in amino acid solution display increased and proliferative activity, with increased collagen production and fibronectin synthesis. In addition, they increase the expression of transforming growth factor beta, the connective tissue growth factor, and of interleukins 6 and 8. These results suggest that hyaluronic acid is involved in many stages, including neoangiogenesis, fibroblast proliferation and differentiation, extracellular matrix deposition, cytokine production and release, and re-epithelialisation. In the field of dentistry, some studies have shown significant advantages of the product, especially in patients with periodontal

disease who show significant bone defects and in patients undergoing surgery for the removal of benign tumors (2, 3).

The need to promote and accelerate the healing of wounds is even more necessary in patients in whom the healing process is inadequate (4). For this reason, in this study, we used SH-AAs in a group of patients with chronic liver disease. Liver failure is a clinical condition that enables a limited compensation of the function of the organ due to the progression of chronic diseases (5, 6). This type of patients are subject to abnormal wound healing due to their liver disease, which exposes them to conditions of malnutrition, hormonal disorders, bilirubin and ammonia intoxication and bleeding diathesis (7). Extraction complications are associated with a loss of organ functions, and abnormalities in drug metabolism, immune response and haemostatic process often occur (8). These conditions characterize chronic liver disease and can influence the physiological processes of post-extraction alveolus healing, thus exposing the wound to a higher risk of complications (9). The purpose of the study is to assess how the use of products based on sodium hyaluronate and aminoacids (HS-AAs) can improve epithelial regeneration and healing of the post-extractive tooth socket.

Key words: socket healing, tooth extraction, liver, amino-acid, sodium hyaluronate, dental care, SH-AA

Corresponding Author:

Dr T. Ruggiero,
Oral Surgery Department,
Department of Surgical Sciences,
University of Turin, Dental School,
Via Nizza 230, 1 - 0100 Turin, Italy
e-mail: tiziana.ruggiero@unito.it

0393-974X (2019)

Copyright © by BIOLIFE, s.a.s.

This publication and/or article is for individual use only and may not be further reproduced without written permission from the copyright holder.

Unauthorized reproduction may result in financial and other penalties
DISCLOSURE: ALL AUTHORS REPORT NO CONFLICTS OF INTEREST RELEVANT TO THIS ARTICLE.

MATERIALS AND METHODS

Research design and management

A split mouth study was conducted in which each patient served as both case and control: one post-extraction alveolus was treated with an SH-AA gel (case site), whilst another was left to naturally heal following the formation of a clot (control site). The choice of alveolus to be treated was made in a controlled randomised manner by an internal use software. The inclusion criteria for the study were: i) patients with severe liver failure, awaiting a liver transplant; ii) platelets higher than 50.000 on the day of surgery; iii) need for extraction of dental elements, no longer recoverable bilateral homologues; iv) giving informed consent to the study. Exclusion criteria were: i) known allergy to one of the components of the compound; ii) inability to attend follow-ups; iii) systemic diseases, in addition to liver failure, which could affect the healing of wounds (e.g. diabetes, chronic renal failure, autoimmune diseases); iv) chronic mucocutaneous diseases; v) inability or unwillingness to provide their informed consent.

The study population was composed of 58 patients referred to the Oral Surgery Section of the Dental School of the University of Turin by the Liver Transplant Center from January 1 to December 31, 2017, as a part of the protocol for candidates to receive a liver transplant. One hundred and sixteen simple bilateral and symmetrical dental extractions were performed. Patients with liver failure prior to transplantation (OLT) had to meet the inclusion and exclusion criteria of the study and agree to be monitored. All patients were informed about the possible use of their data for clinical studies and signed an informed consent form. The patient data were anonymized before analysis. The analysis was performed in accordance with the local institutional review board standards and conformed to the Declaration of Helsinki of 1975 and subsequent modifications.

Surgical protocol

The included patients were registered in a computerized clinical file which recorded information on age, gender, smoking habits, alcohol consumption, systemic pathologies, and the use of any drugs. Each patient then attended a program of professional dental hygiene to nullify differences in preoperative hygiene conditions, after which a thorough clinical and radiologic evaluation and

digital case history for each patient was filed containing oral and dental parameters: periodontal screening and recording code; conditions of untreatable teeth undergoing extraction (e.g., presence of infections, carious processes, or periodontal affection); difficulty of extraction (based on crown integrity, root morphology, space, and patient compliance); and symptoms.

Alveolar nerve block infiltration was administered with local or regional anesthesia, depending on the dental arch, using 2% mepivacaine. Mepivacaine does not contain epinephrine, therefore, it was used to prevent restriction of the blood supply (10). To prevent interference with the healing process, no intraligamentous or intrapapillary infiltrations were performed. Non-traumatic bilateral extractions were accomplished without elevation of full-thickness flaps to preserve the bone ridges and soft tissue at the two sites. Surgery was performed on the treatment and control sides at the same time. After socket curettage to remove granulation tissue, a millimeter probe was used to measure the socket diameters (maximum mesiodistal and buccolingual extensions).

The SH-AAs gel in a syringe (15 ml) was applied within the socket chosen as the study site, and the membrane was laid above within the socket wall. After 5 min of compression with sterile cotton, bleeding was evaluated as spontaneous, induced by palpation, or absent. Accurate postoperative recommendations were provided to the patients. No pharmacologic therapy was prescribed, and recourse to antibiotics was considered a negative postoperative parameter, a sign of postoperative complications from infection. Patients were taught to apply SH-AAs gel on the study site 3 times a day, every 8 hours, for 7 days. After the extractions, each patient underwent a precise follow-up program: 4 sessions conducted at 7, 14, and 21 days or until socket closure. Each session included measurements of the socket in the study and control sites. Pain was evaluated by the patients using a VAS, (11) which distinguished the study and control sockets, for 7 consecutive days, with day 0 considered the day of extraction, after resolution of the effects of the anesthesia. The patients' general satisfaction was evaluated with a questionnaire administered after extraction. Patients were asked to state any differences noticed in bleeding or pain between the 2 sites and to state which technique they would choose for a future extraction. Additional control sessions after postoperative day 21 until the achievement of socket

epithelialization and the need for antibiotic administration or for surgical re-intervention in cases of alveolitis were considered possible negative postoperative parameters.

Statistical analysis

For the statistical analysis of the oral vestibule and mesiodistal diameters at 0, 7, 14 and 21 days and on the accompanying pain over a period of one week, the data were expressed as means and standard deviations. Being a case-control trial, their comparison involved the Student's paired data *t*-test, which reduces the problem of biological variability between the various patients. The values of the probability of random difference *p* were considered significant for $p < 0.05$.

RESULTS

Oral vestibule diameters. The results of the oral vestibular diameters of the post extractive sites of the treated group (case site) and untreated group (control site) at time zero (T0), at 7 days (T1), at 14 days (T2) and at 21 days (T3) are shown in Table I. Fig. 1 shows the different trend in oral vestibule diameters at the 4 points (time zero, 1 week, 2 weeks, 3 weeks), respectively, for the case site and for the control site. The dashed line shows the inclination that the straight line would likely have taken had the SH-AAs gel treatment continued for more than one week.

Mesiodistal diameters. The results of the mesiodistal diameters of the post extractive sites of the treated group (case site) and untreated group (control site) at time zero, and at 7, 14 and 21 days are shown in Table I. Fig. 1 shows the diverse trend in mesiodistal diameters at the 4 time-points, respectively, for the case site and for the control site. The dashed line shows the inclination that the straight line would likely have taken had the HA-AA gel treatment continued for more than one week.

Upper and lower arch comparison. There are no statistically significant differences when comparing the upper arch with the lower arch in either the case site or in the control site. The force of gravity seems to have no influence on the healing mechanisms, therefore, the application of the product promotes faster epithelialization, regardless of the position of the dental elements in the arch.

Comparison of single-/multi-rooted dental elements. Table II shows the variations in the oral vestibule and mesiodistal diameters in the time interval ranging from time zero to 21 days, divided between single-rooted and multi-rooted dental elements; *p*₁ represents the probability associated with comparing the single-rooted dental elements in the case site and in the control site; the same is carried out for multi-rooted elements; this is to understand whether the application of the product gives the same results for both single-rooted and multi-rooted elements. *p*₂ represents the probability by comparing single-rooted and multi-rooted dental elements of the case site; the same was carried out for the control site; this is to understand whether the alveolar dimensions and morphology could affect the speed of healing.

VAS Scale. The intention was to establish whether the use of the product could give benefits, not only in

Table I. Alveolar diameter reduction. The values highlighted in bold represent the statistically significant associated probabilities.

Alveolar diameters			
ΔT	Case site (mm)	Control site (mm)	Paired <i>t</i> -test
T0	6.72±1.95	6.60 ± 1.88	0.77
T1	3.89±1.73	4.64 ± 2.03	<0.0001
T2	2.09±1.31	3.07 ± 1.51	<0.0001
T3	0.58±1.11	1.21 ± 1.25	<0.0001
Mesiodistal diameters			
ΔT	Case site (mm)	Control site (mm)	Paired <i>t</i> -test
T0	6.56 ± 2.04	6.51 ± 2.03	0.62
T1	3.61±1.84	4.69 ± 2.04	≤10⁻⁷
T2	1.74±1.54	2.82 ± 1.70	≤10⁻⁷
T3	0.44±1.02	1.16 ± 1.25	2.31x10⁻³

T1:7 days, T2:14 days; T3:21 days.

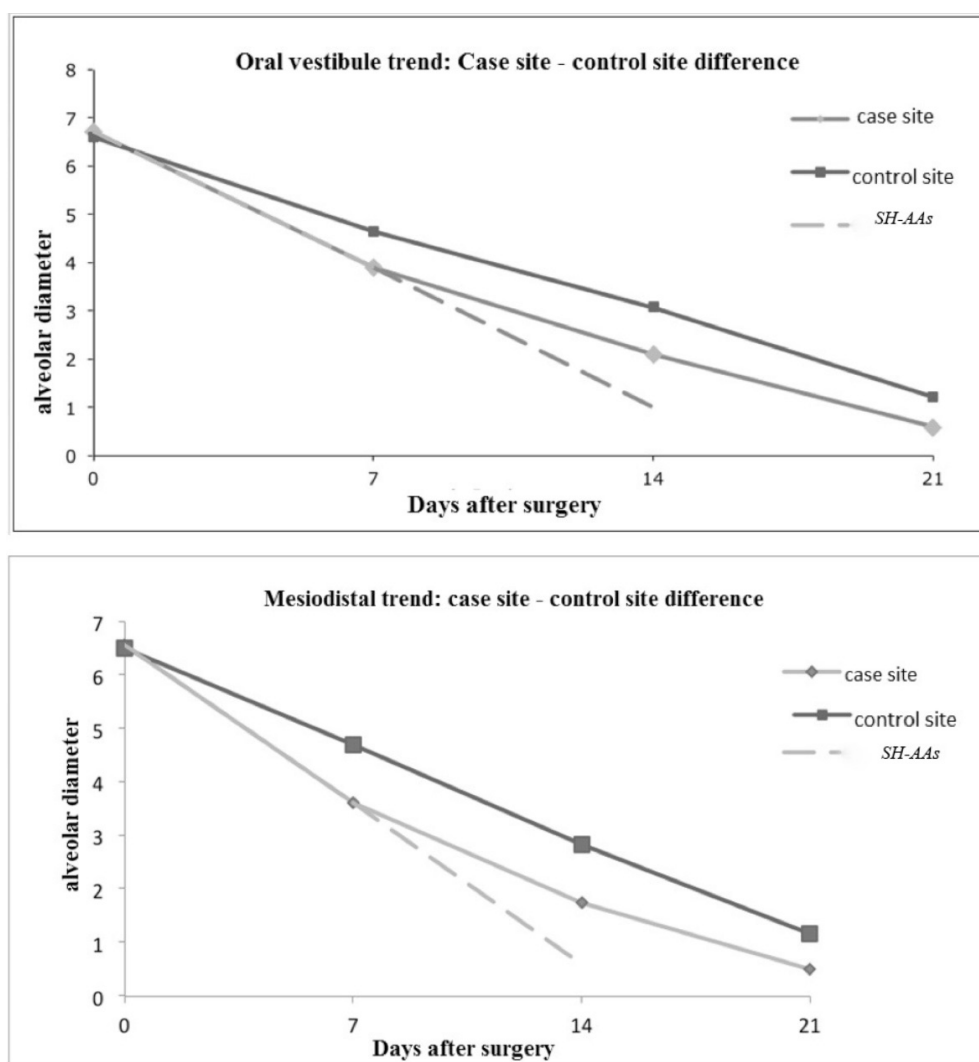


Fig. 1. Trend in oral vestibule and mesiodistal diameters. The divergence between the two lines is significant in the first 7 days; subsequently, the lines are parallel. little squares: case site; big squares: control site; dashed lines: probable healing if patients continued application of SH-AAs.

terms of healing, but also in terms of post-operative pain, given that a faster and better quality healing has a positive effect on this aspect also. During the first week after surgery, the patient was advised to report the intensity of pain by recording it on the VAS scale (assessed on a scale between 0 and 10 cm), referring to both the case site and to the control site. The trend in pain in both the case site and in the control site in the first 7 days are shown in Table II and Fig. 2. The values were statistically significant only in the first 3 days; from the fourth to the seventh days, the values were no longer significant.

DISCUSSION

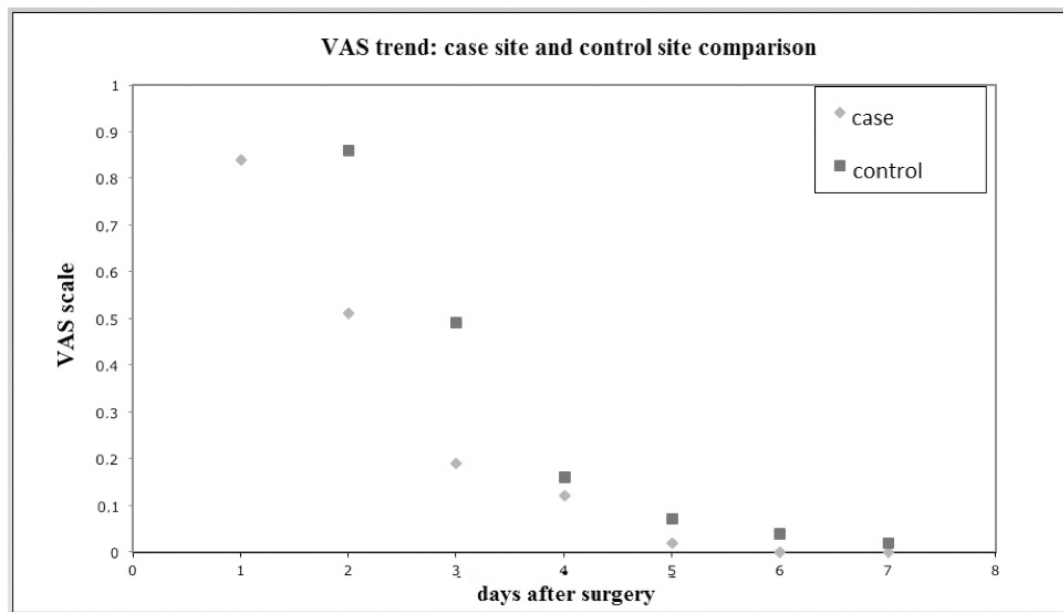
The main purpose of SH-AA gel is to improve healing, from qualitative and temporal points of view. Sodium hyaluronate (SH) contributes by acting with an anti-edematous, encouraging vascularization and promoting epithelial healing (2). It is reasonable to think that if a surgical site epithelializes within a short space of time, it is less subject to healing problems. With greater reason, oversight has previously occurred for patients who had most need to be guided in their recovery, such as

Table II. The comparison of single-/multi-rooted dental elements in speed healing and comparison single-rooted and multi-rooted elements.

ΔT	Case site	Control site	Paired t -test	t -test on average values
Day 1	0.84 ± 0.29	1 ± 0.41	7.61×10^{-5}	3.54×10^{-4}
Day 2	0.51 ± 0.50	0.86 ± 0.44	2.09×10^{-5}	1.30×10^{-4}
Day 3	0.19 ± 0.40	0.49 ± 0.50	2.54×10^{-4}	6.61×10^{-4}
Day 4	0.12 ± 0.33	0.16 ± 0.37	0.53	0.59
Day 5	0.02 ± 0.13	0.07 ± 0.26	0.18	0.17
Day 6	0	0.04 ± 0.019	0.16	0.16
Day 7	0	0.02 ± 0.13	0.32	0.2

ΔT	Tooth	Vestibule/oral			Mesio/distal		
		case site (mm)	control site (mm)	p1	case site (mm)	control site (mm)	p1
(0-21 days)	single-rooted	$96 \pm 87\%$	$89 \pm 14\%$	3×10^{-3}	$98 \pm 6\%$	$87 \pm 14\%$	4×10^{-3}
	multi-rooted	$89 \pm 11\%$	$78 \pm 12\%$	13×10^{-3}	$88 \pm 17\%$	79 ± 10	4×10^{-3}
	p2	2.65×10^{-3}	7.80×10^{-3}		5×10^{-3}	5.2×10^{-3}	

The values highlighted in bold represent the statistically significant associated probabilities.

**Fig. 2.** Trend in pain. The difference was statistically significant in the first 3 days but not from the fourth to the seventh days. little squares: case site; big squares: control site.

those with liver disease (12). The clinical sensation, confirmed by this study, shows that the effectiveness of the product is maximal, especially in the first days, from both an epithelial healing point of view and from a VAS point of view. With regard to the trend in diameters, the statistical survey shows that the significance is valid in all 3 time-points taken into account (days 7, 14 and 21). Since the product was only applied for the first week, the intention was to understand in which time interval the product was most effective. What was expected (and confirmed by the statistical analysis) was that, in the first time interval, the difference would be maximal and would gradually decrease during subsequent time intervals. In the subsequent time intervals, the associated probabilities tend to become less significant, but always remain significant in all time intervals, except for between days 7 and 14 (Table I, Fig. 1). The comparison of single-/multi-rooted dental elements was carried out to understand whether there is also a correlation between alveolar size and shape. A small alveolus, with the same conditions, heals sooner than a large alveolus (Table II). This can be explained simply by the fact that larger alveoli, with a different alveolar morphology, require more “repairing cells” and, therefore, more time. Then, the intention was to understand whether this product is equally effective in single-/multi-rooted elements. Also in this case (Table II), the associated probabilities were statistically significant: the speed of epithelial healing is influenced by the use of SH-AAAs, in both oral vestibule and mesiodistal diameters. The gel promotes an improvement that is always statistically significant from a healing point of view, but healing differs depending on whether the element is single- or multi-rooted, with a preference for small alveoli with single root. If a wound remains constantly covered by a protective gel it is less subject to the intraoral environment; if this product also acts as a healing mediator, it is clear that the risk of superinfection is lower. This translates into the fact that healing optimally starts with practical advantages in terms of post-operative sensitivity. The gel exerts its effect of reducing the perception of pain only in the first 3 days. During subsequent follow-ups the associated probability values between the case site and the

control site are non-significant. This can be explained by the fact that the surgical damage to the patient is minimal, due to the minimally invasive nature of the surgical act of extraction.

REFERENCES

1. Price RD, Myers S, Leigh IM, Navsaria HA. The role of hyaluronic acid in wound healing: assessment of clinical evidence. *Am J Clin Dermatol* 2005; 6(6):393-402.
2. Colella G, Vicidomini A, Soro V, Lanza A, Cirillo N. Molecular insights into the effects of sodium hyaluronate preparations in keratinocytes. *Clin Exp Dermatol* 2012; 37(5):516-20.
3. Kim J-J, Song HY, Ben Amara H, Kyung-Rim K, Koo K-T. Hyaluronic Acid Improves Bone Formation in Extraction Sockets With Chronic Pathology: A Pilot Study in Dogs. *J Periodontol* 2016; 87(7):790-5.
4. Vazquez JR, Short B, Findlow AH, Nixon BP, Boulton AJM, Armstrong DG. Outcomes of hyaluronan therapy in diabetic foot wounds. *Diabetes Res Clin Pract* 2003; 59(2):123-27.
5. Jalan R, Fernandez J, Wiest R, et al. Bacterial infections in cirrhosis: a position statement based on the EASL Special Conference 2013. *J Hepatol* 2014; 60(6):1310-24.
6. Perdigão JPV, de Almeida PC, Rocha TDS, et al. Postoperative bleeding after dental extraction in liver pretransplant patients. *J Oral Maxillofac Surg Off J Am Assoc Oral Maxillofac Surg* 2012; 70(3):e177-84.
7. Pereira TDSF, Pelinsari FCM, Ruas BM, et al. Postoperative complications after dental extraction in liver pretransplant patients. *Spec Care Dent Off Publ Am Assoc Hosp Dent Acad Dent Handicap Am Soc Geriatr Dent* 2016; 36(5):277-81.
8. Cocero N, Pucci F, Messina M, Pollio B, Mozzati M, Bergamasco L. Autologous plasma rich in growth factors in the prevention of severe bleeding after teeth extractions in patients with bleeding disorders: a controlled comparison with fibrin glue. *Blood Transfus Trasfus Sanguine* 2015; 13(2):287-94.
9. Helenius-Hietala J, Åberg F, Meurman JH, Nordin A, Isoniemi H. Oral surgery in liver transplant candidates: a retrospective study on delayed bleeding and other complications. *Oral Surg Oral Med Oral Pathol Oral*

- Radiol 2016; 121(5):490-95.
10. Colbath AC, Wittenburg LA, Gold JR, McIlwraith CW, Moorman VJ. The effects of mepivacaine hydrochloride on antimicrobial activity and mechanical nociceptive threshold during amikacin sulfate regional limb perfusion in the horse. *Vet Surg* 2016; 45(6):798-803.
 11. Aicher B, Peil H, Peil B, Diener H-C. Pain measurement: Visual Analogue Scale (VAS) and Verbal Rating Scale (VRS) in clinical trials with OTC analgesics in headache. *Cephalalgia Int J Headache*. 2012; 32(3):185-97.
 12. Silva Santos PS da, Fernandes KS, Gallottini MHC. Assessment and management of oral health in liver transplant candidates. *J Appl Oral Sci Rev FOB*. 2012; 20(2):241-45.